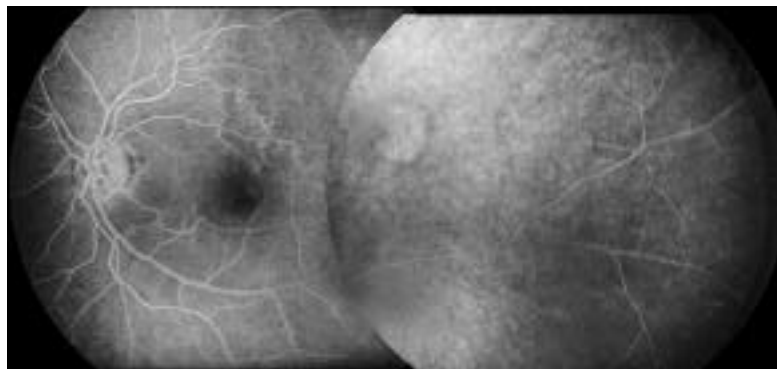
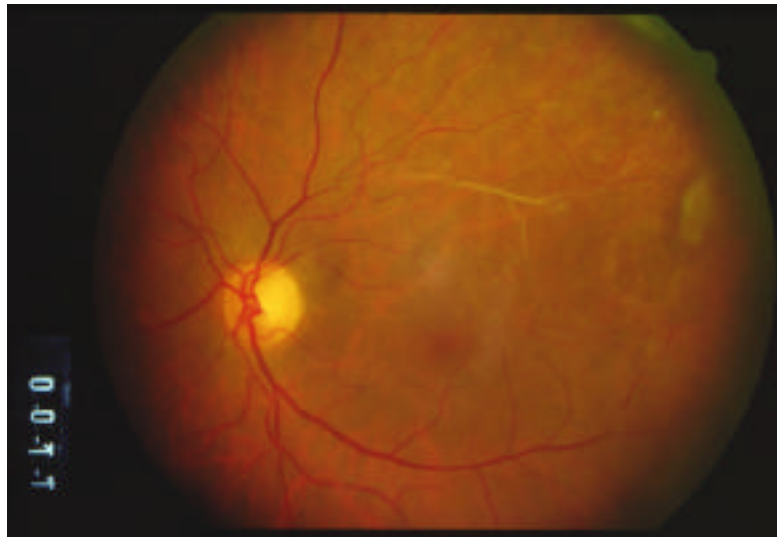
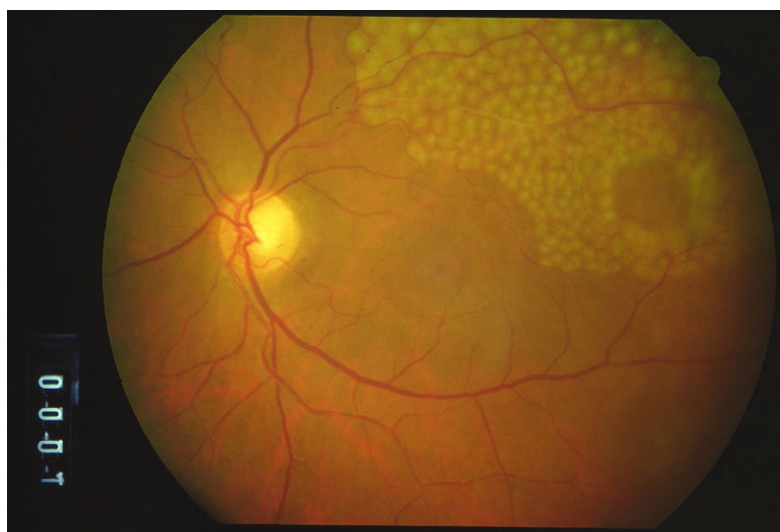
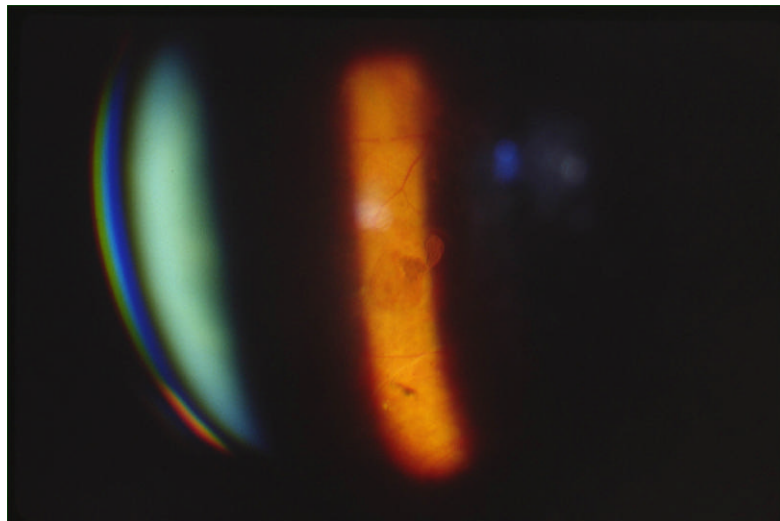
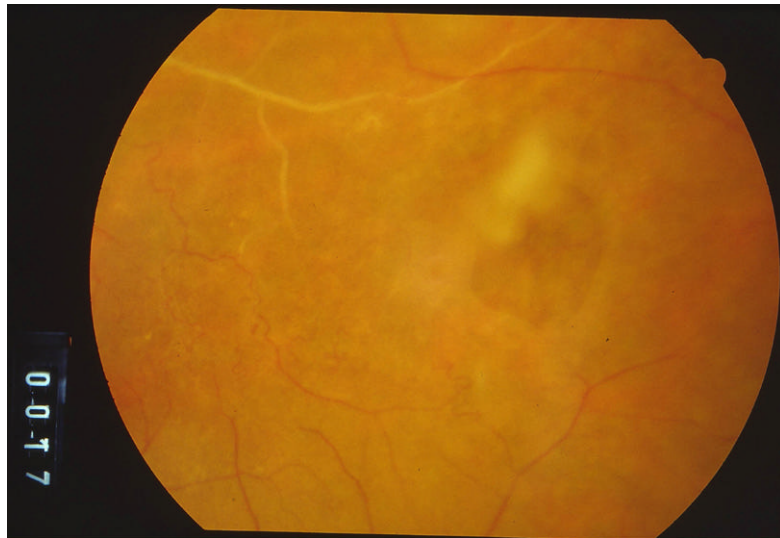

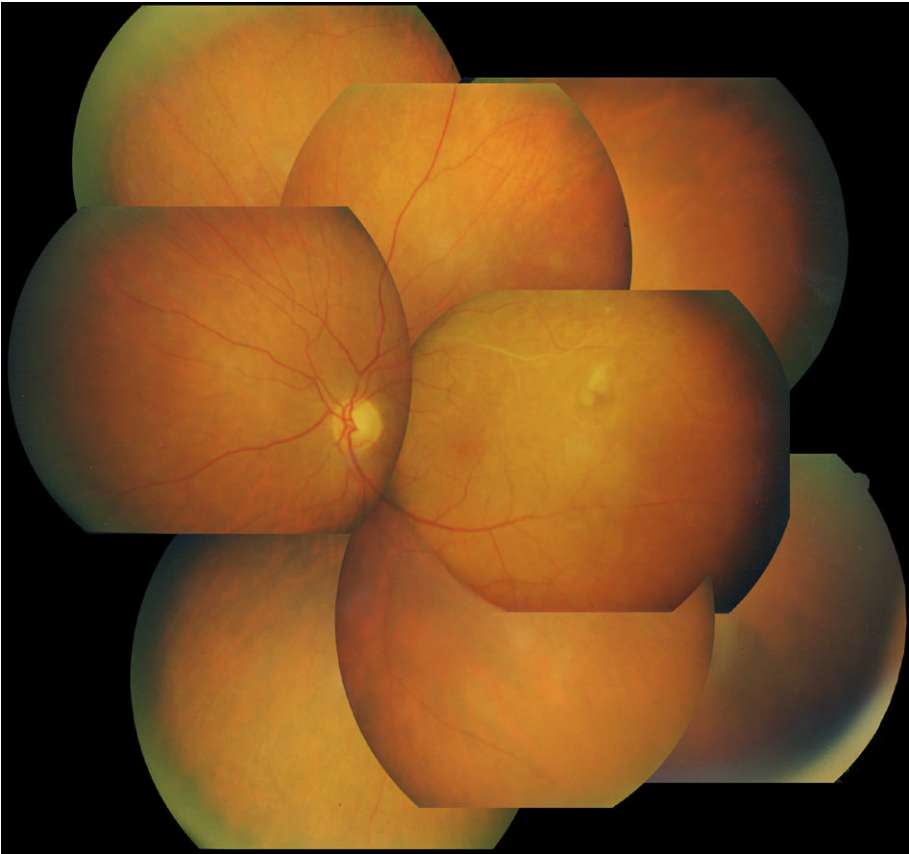


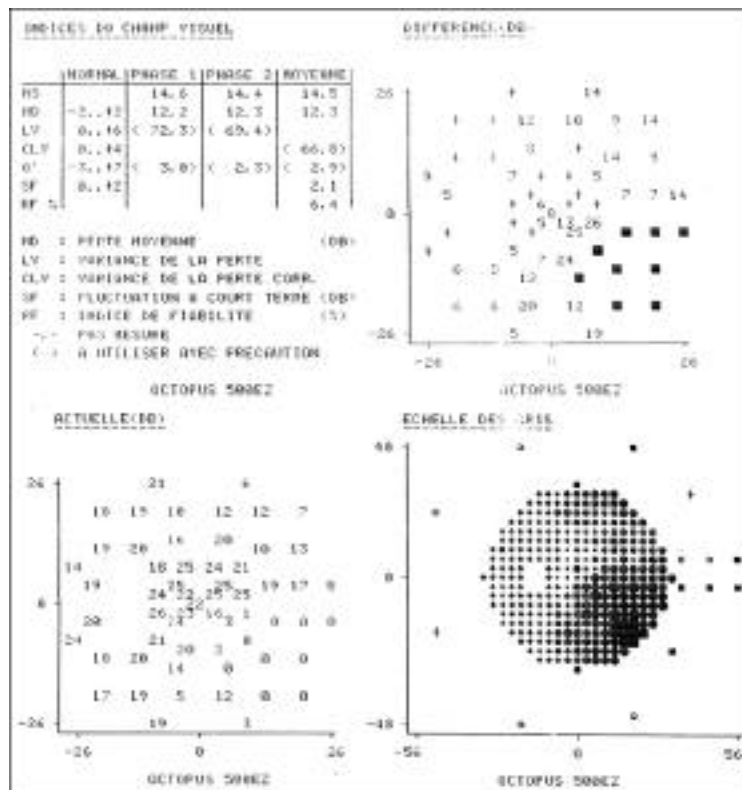
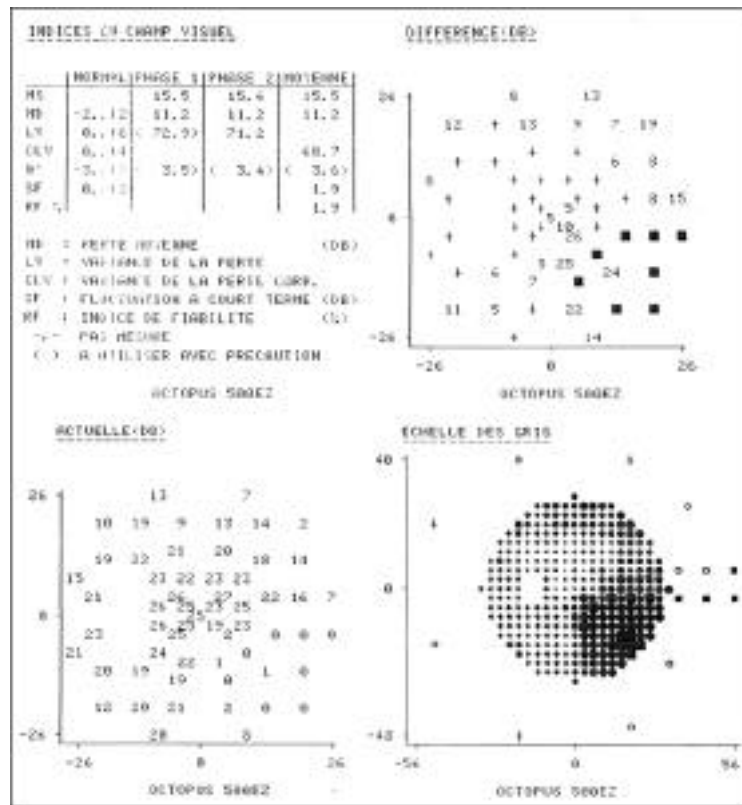
NUM.REFERENCIA: 38

EDAD: 64		SEXO: 2	OJO: 2
ANTECD.CV: 2 DIABETES: 2 H <sup>a</sup> .HTA: 1 HTA.EXPL: 1 DISLIPEMIA: 2 TABAQUISMO: 2	SCTRL: 1 SDISMBRUS: 2 SDISMPROGR: 2 SESCOT: 2 SMETAMORF: 2 SMIODESOP: 2	RTEMP: 1 VITREO: 2	INFARTO FS NERV:2 EXUDS.DUROS: 2 ISQUEMIA RETINAL: 3 TIPO OBSTRUCCION: 2 EDEMA MACULAR: 2 ISQUEMIA MACULAR: 2 ARC. PERIFOVEAL(CUADS): 1 NEOVASC. RETINAL: 2 ENTRECRUZ.AV/VA: 1 ENTRECRUZ. OTRA RV: 2 RESPETA FOVEA: 2 VENA DRENAJE: 1
AVLINI: 0,95 AVLFIN: 0,95 AVPINI:1 AVPFIN: 1 REFRACCION: 1	TOCTOP: 6 EVOL (t HASTA FCG): 7,00 Nº SESIONES FCG: 1 SEGUIM (tFCG-FINAL): 445,00 COMPLICS FCG: 2		
TG(mmHg): 14	OJOCL: 1 VITREO CONTRALAT: 1		



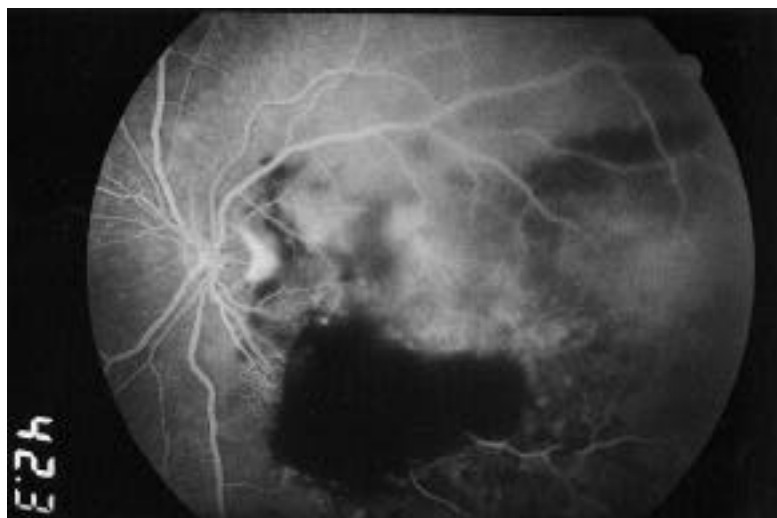
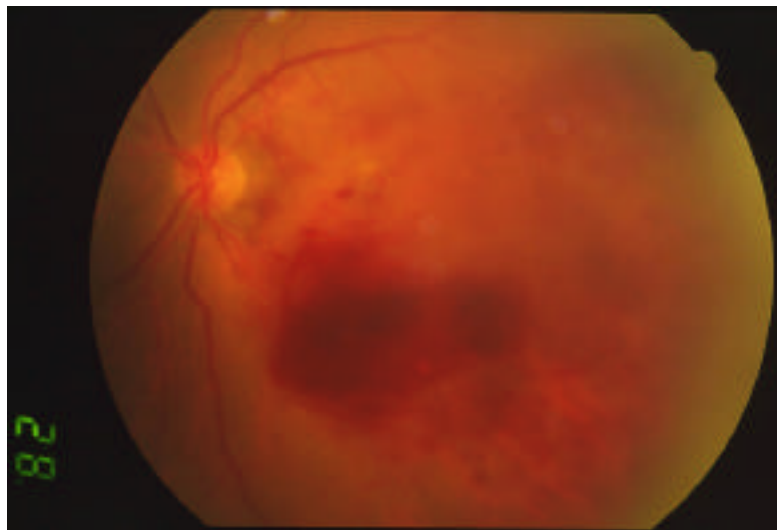


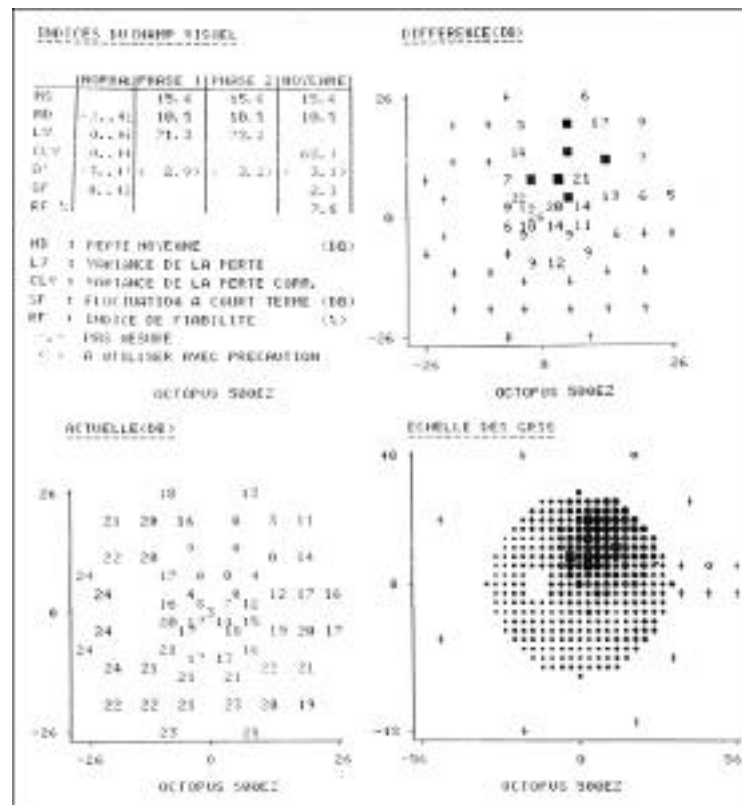
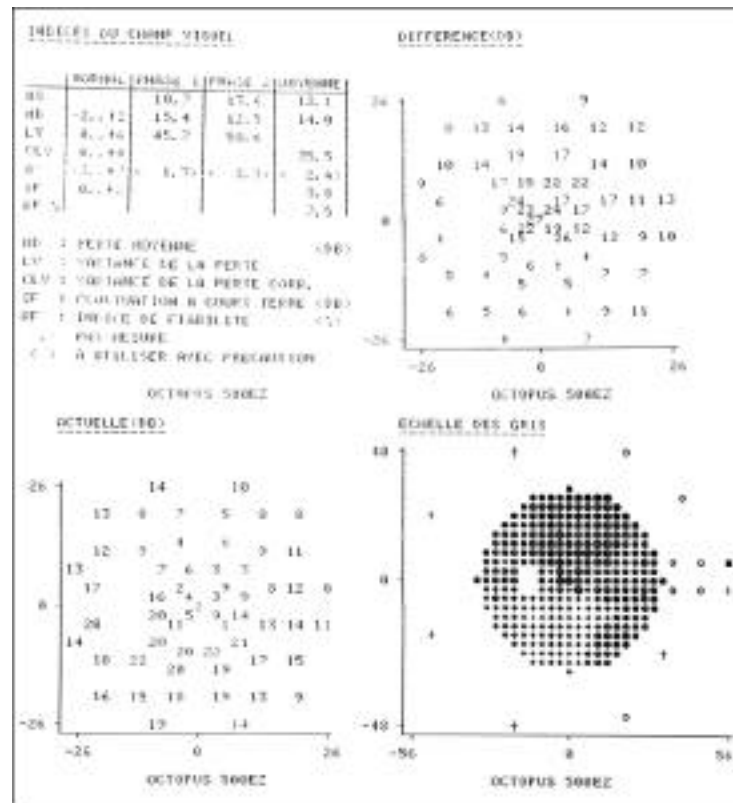




NUM.REFERENCIA: 40

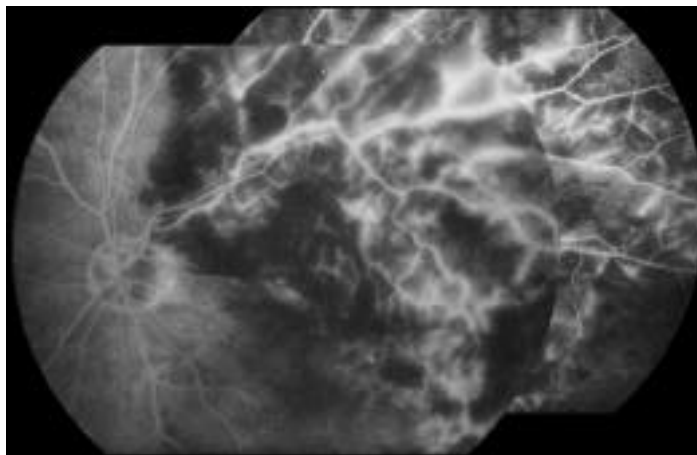
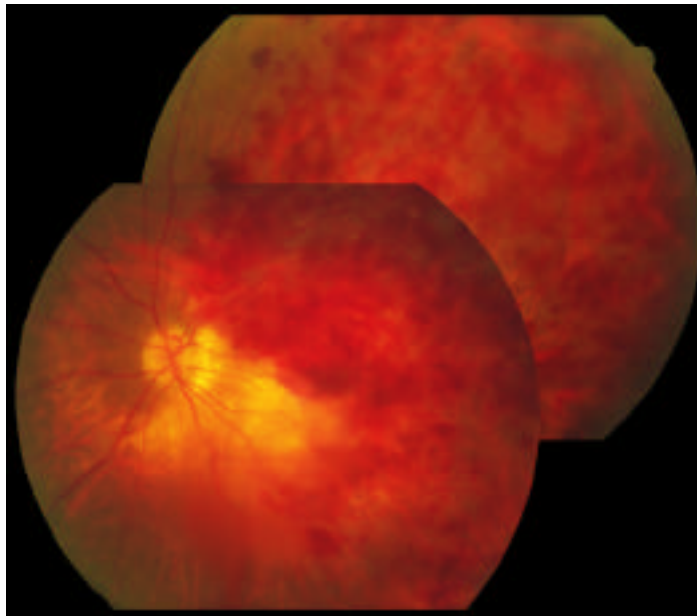
EDAD: 72	SEXO: 2	OJO: 2
ANTECD.CV: 1 DIABETES: 2 H <sup>a</sup> .HTA: 2 HTA.EXPL: 2 DISLIPEMIA: 2 TABAQUISMO: 2	SCTRL: 2 SDISMBRUS: 1 SDISMPROGR: 2 SESCOT: 2 SMETAMORF: 2 SMIODESOP: 2	RTEMP: 2 VITREO: 1
AVLINI: 0,08 AVLFIN: 0,05 AVPINI:6 AVPFIN: 9 REFRACCION: 3	TOCTOP: 83 EVOL (t HASTA FCG): 157,00 N° SESIONES FCG: 1 SEGUIM (tFCG-FINAL): 227,00 COMPLICS FCG: 2	INFARTO FS NERV:2 EXUDS.DUROS: 2 ISQUEMIA RETINAL: 3 TIPO OBSTRUCCION: 2 EDEMA MACULAR: 1 ISQUEMIA MACULAR: 1 ARC. PERIFOVEAL(CUADS): 4 NEOVASC. RETINAL: 2 ENTRECRUZ.AV/VA: 1 ENTRECRUZ. OTRA RV: 2 RESPETA FOVEA: 2 VENA DRENAJE: 2
TG(mmHg): 18	OJOCL: 1 VITREO CONTRALAT: 1	

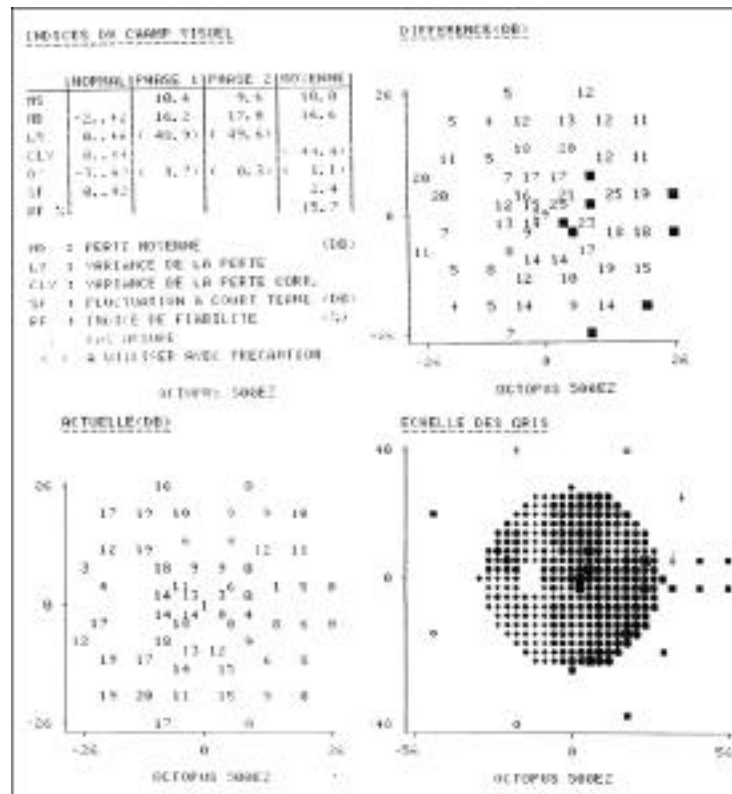
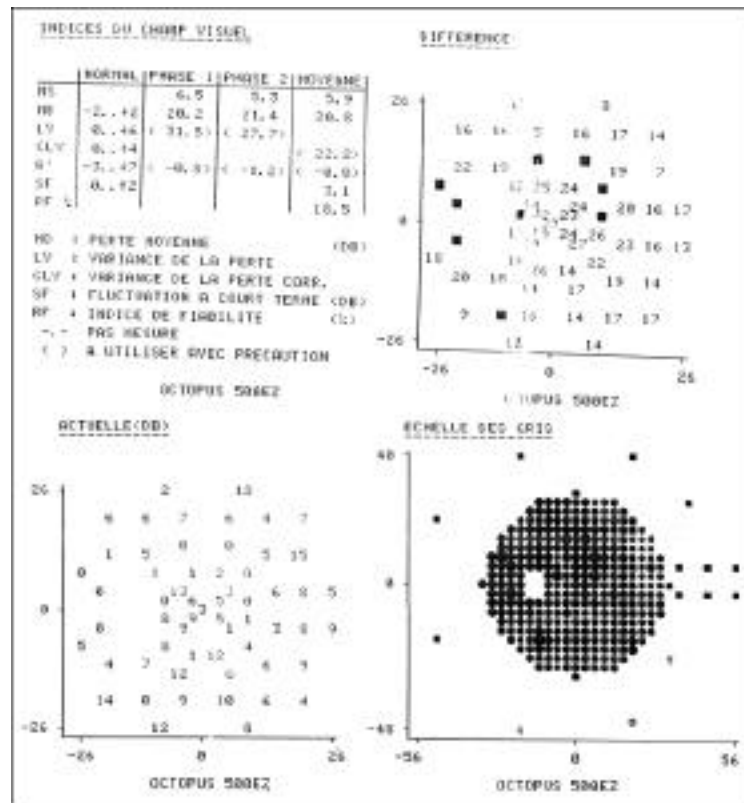




NUM.REFERENCIA: 41

EDAD: 65	SEXO: 2	OJO: 2
ANTECD.CV: 2 DIABETES: 2 H <sup>a</sup> .HTA: 2 HTA.EXPL: 2 DISLIPEMIA: 2 TABAQUISMO: 2	SCTRL: 2 SDISMBRUS: 1 SDISMPROGR: 2 SESCOT: 2 SMETAMORF: 2 SMIODESOP: 1	RTEMP: 1 VITREO: 3
AVLINI: 0,01 AVLFIN: 0,05 AVPINI:0 AVPFIN: 4 REFRACCION: 3	TOCTOP: 16 EVOL (t HASTA FCG): 99,00 Nº SESIONES FCG: 2 SEGUIM (tFCG-FINAL): 1339,0 COMPLICS FCG: 2	INFARTO FS NERV:1 EXUDS.DUROS: 2 ISQUEMIA RETINAL: 3 TIPO OBSTRUCCION: 2 EDEMA MACULAR: 2 ISQUEMIA MACULAR: 1 ARC. PERIFOVEAL(CUADS): 4 NEOVASC. RETINAL: 2 ENTRECRUZ.AV/VA: 1 ENTRECRUZ. OTRA RV: 1 RESPETA FOVEA: 2 VENA DRENAJE: 2
TG(mmHg): 16	OJOCL: 1 VITREO CONTRALAT: 3	

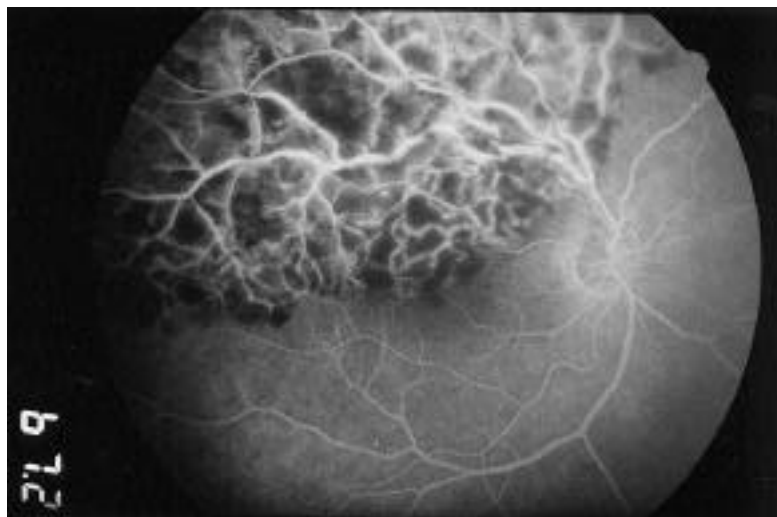
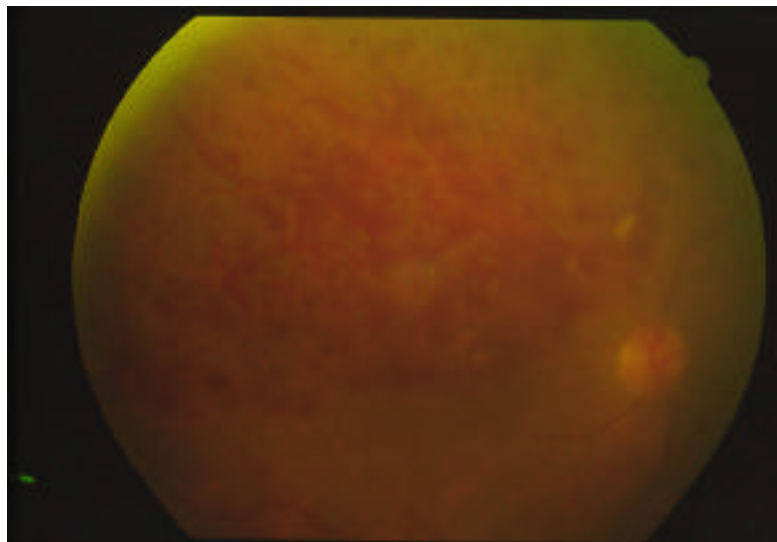


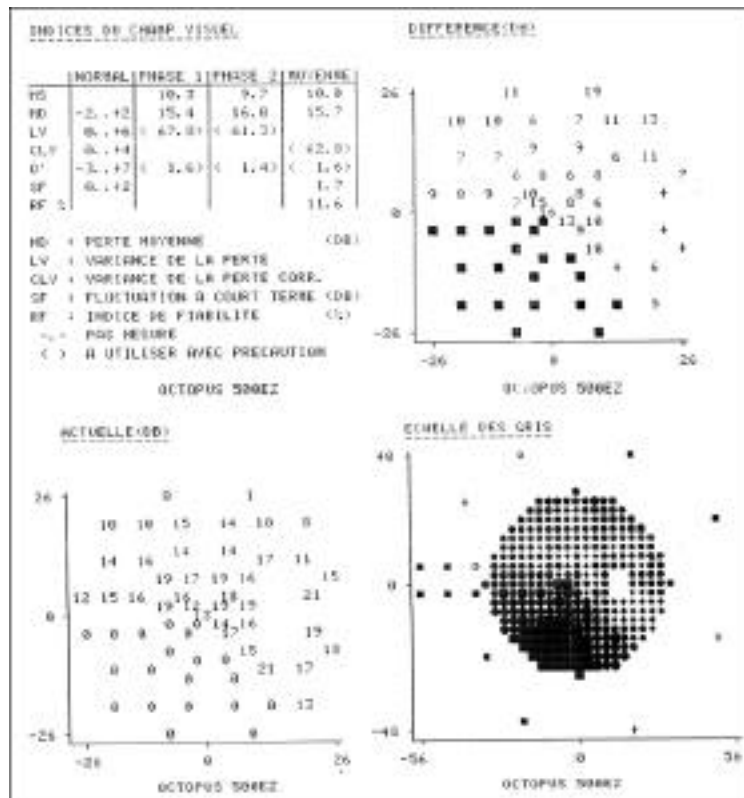
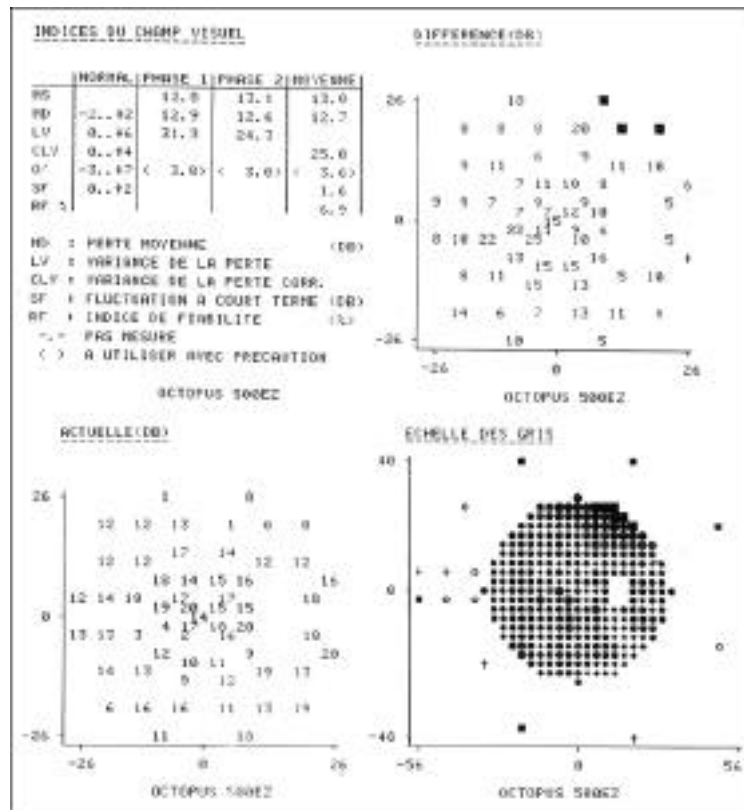




NUM.REFERENCIA: 42

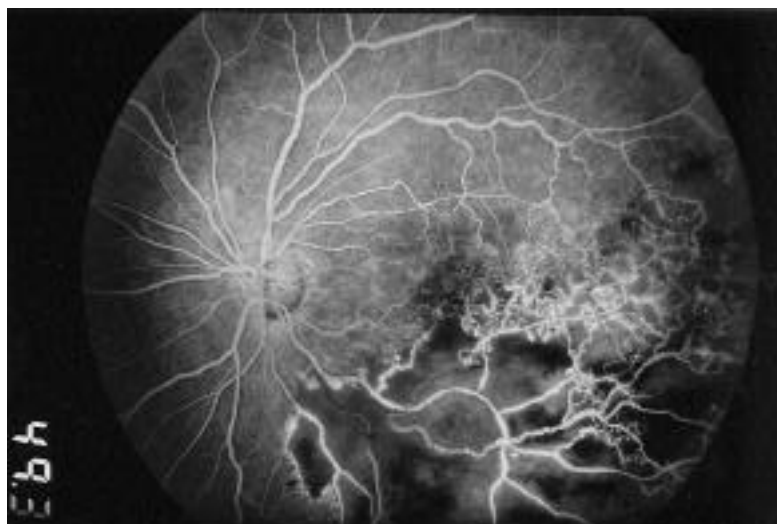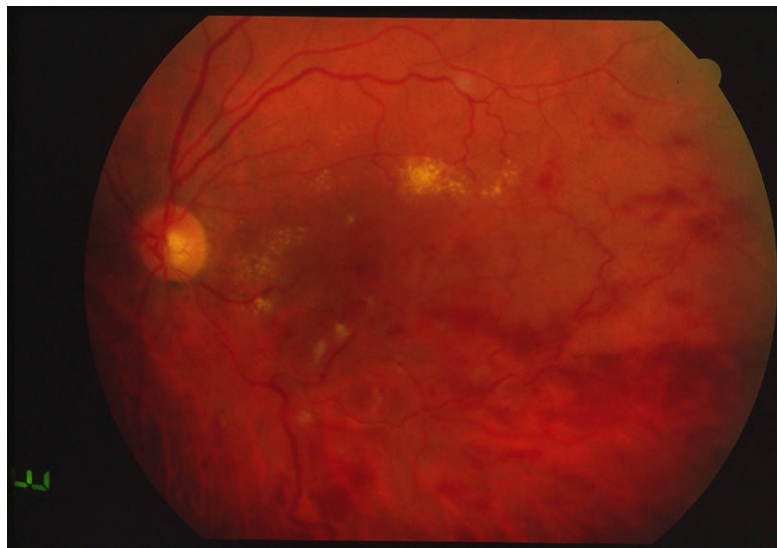
EDAD: 80		SEXO: 1	OJO: 1
ANTECD.CV: 2 DIABETES: 1 H <sup>a</sup> .HTA: 1 HTA.EXPL: 2 DISLIPEMIA: 2 TABAQUISMO: 2	SCTRL: 2 SDISMBRUS: 2 SDISMPROGR: 1 SESCOT: 2 SMETAMORF: 1 SMIODESOP: 2	RTEMP: 1 VITREO: 1	
AVLINI: 0,06 AVLFIN: 0,03 AVPINI:6 AVPFIN: 9 REFRACCION: 2	TOCTOP: 77 EVOL (t HASTA FCG): 78,00 N° SESIONES FCG: 1 SEGUIM (tFCG-FINAL): 141,00 COMPLICS FCG: 2	INFARTO FS NERV:1 EXUDS.DUROS: 2 ISQUEMIA RETINAL: 3 TIPO OBSTRUCCION: 2 EDEMA MACULAR: 2 ISQUEMIA MACULAR: 1 ARC. PERIFOVEAL(CUADS): 4 NEOVASC. RETINAL: 2 ENTRECRUZ.AV/VA: 1 ENTRECRUZ. OTRA RV: 1 RESPETA FOVEA: 2 VENA DRENAJE: 2	
TG(mmHg): 13	OJOCL: 1 VITREO CONTRALAT: 1		

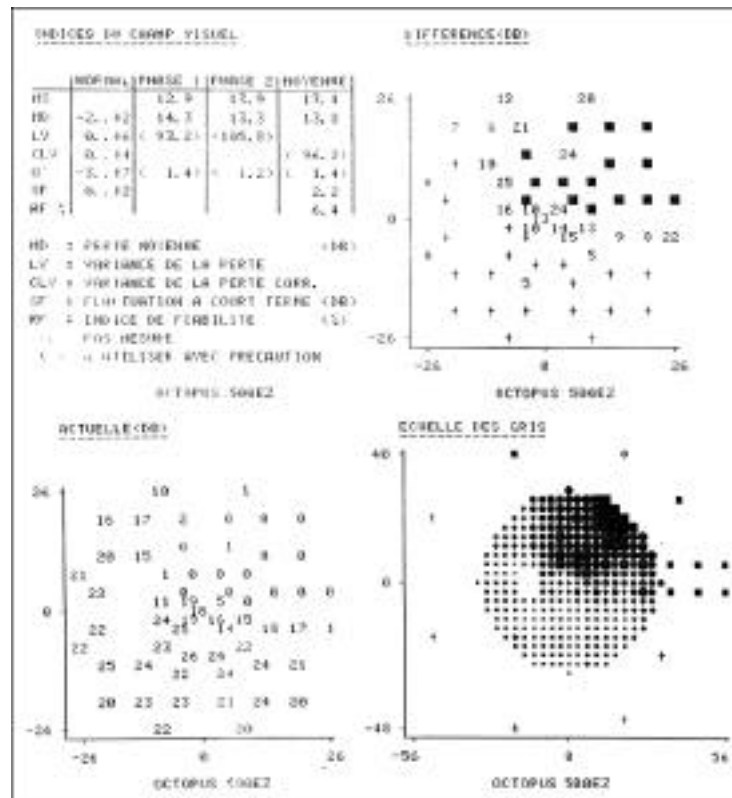
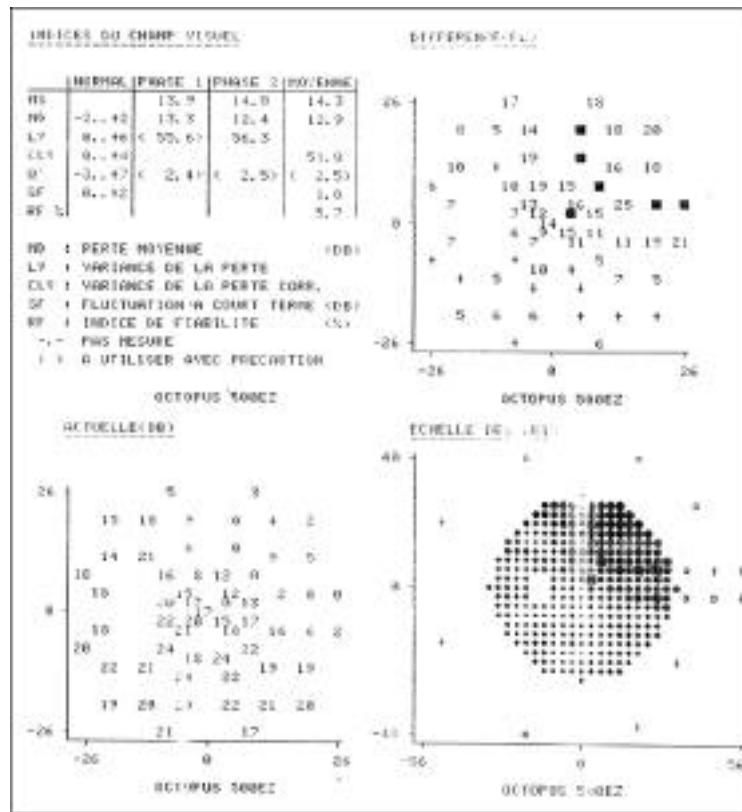




NUM.REFERENCIA: 43

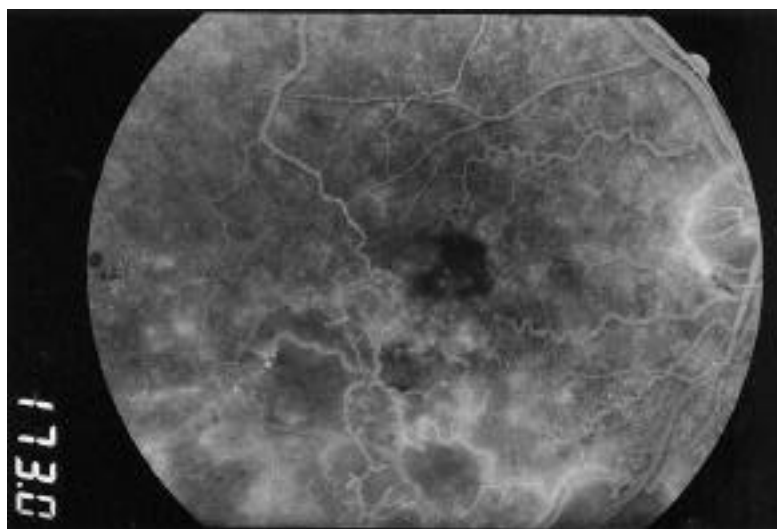
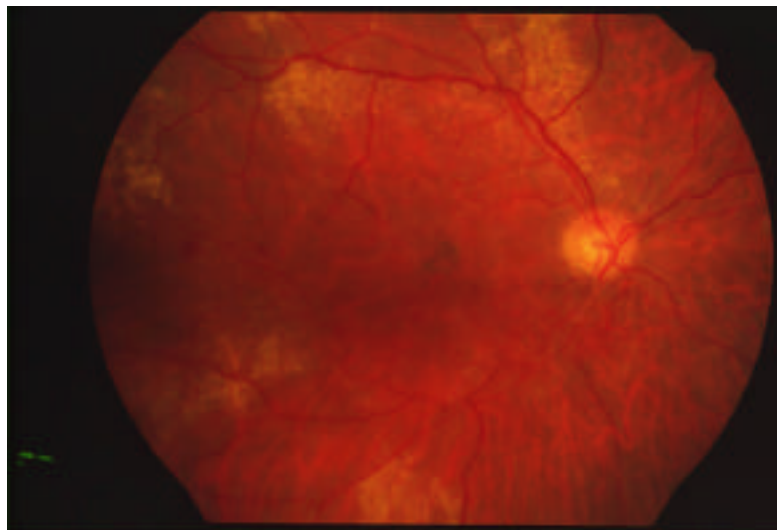EDAD: 58		SEXO: 2	OJO: 2
ANTECD.CV: 2 DIABETES: 2 H <sup>a</sup> .HTA: 2 HTA.EXPL: 2 DISLIPEMIA: 2 TABAQUISMO: 2	SCTRL: 1 SDISMBRUS: 2 SDISMPROGR: 2 SESCOT: 2 SMETAMORF: 2 SMIODESOP: 2	RTEMP: 2 VITREO: 3	
AVLINI: 0,3 AVLFIN: 0,25 AVPINI: 2 AVPFIN: 3 REFRACCION: 2	TOCTOP: 366 EVOL (t HASTA FCG): 392,00 N° SESIONES FCG: 2 SEGUIM (tFCG-FINAL): 1598,0 COMPLICS FCG: 2	INFARTO FS NERV:1 EXUDS.DUROS: 1 ISQUEMIA RETINAL: 3 TIPO OBSTRUCCION: 2 EDEMA MACULAR: 1 ISQUEMIA MACULAR: 1 ARC. PERIFOVEAL(CUADS): 4 NEOVASC. RETINAL: 2 ENTRECRUZ.AV/VA: 1 ENTRECRUZ. OTRA RV: 1 RESPETA FOVEA: 2 VENA DRENAJE: 1	
TG(mmHg): 12	OJOCL: 1 VITREO CONTRALAT: 1		

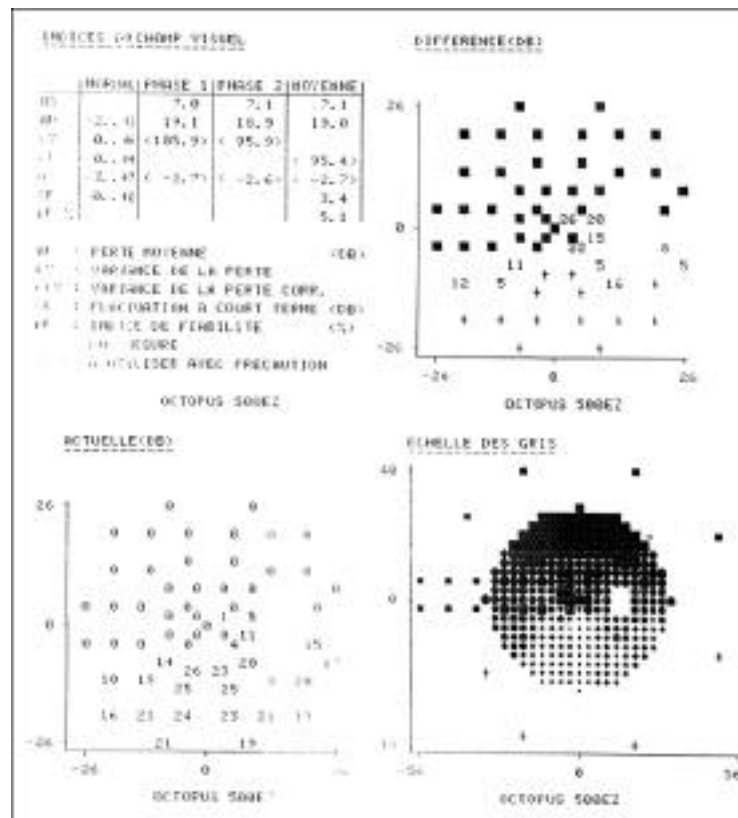
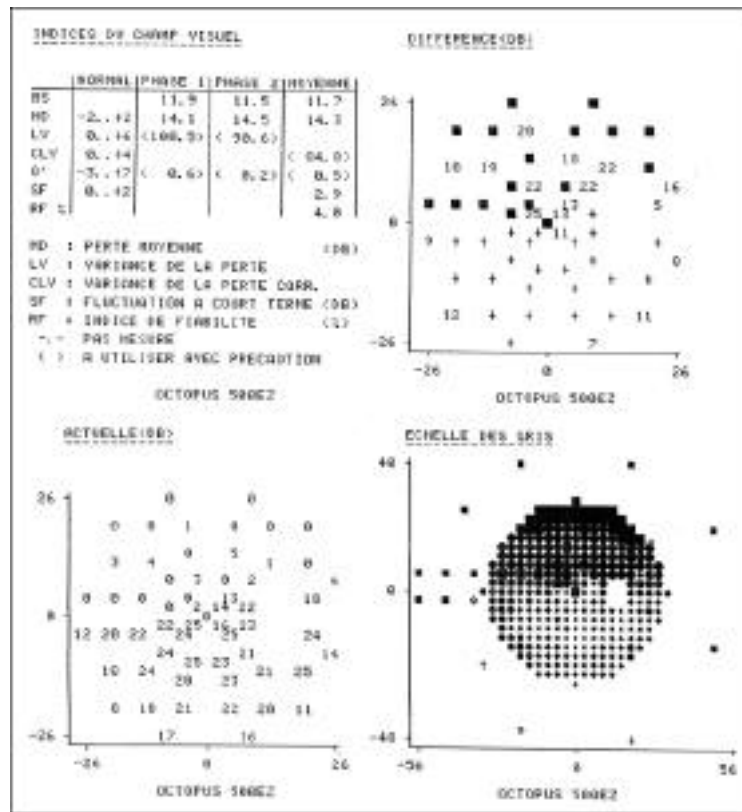




NUM.REFERENCIA: 45

EDAD: 73	SEXO: 2	OJO: 1
ANTECD.CV: 2 DIABETES: 1 H <sup>a</sup> .HTA: 1 HTA.EXPL: 2 DISLIPEMIA: 1 TABAQUISMO: 2	SCTRL: 2 SDISMBRUS: 2 SDISMPROGR: 1 SESCOT: 2 SMETAMORF: 2 SMIODESOP: 1	RTEMP: 2 VITREO: 2
AVLINI: 0,05 AVLFIN: 0,04 AVPINI: 7 AVPFIN: 8 REFRACCION: 2	TOCTOP: 730 EVOL (t HASTA FCG): 733,00 Nº SESIONES FCG: 1 SEGUIM (tFCG-FINAL): 902,00 COMPLICS FCG: 2	INFARTO FS NERV: 2 EXUDS.DUROS: 2 ISQUEMIA RETINAL: 3 TIPO OBSTRUCCION: 2 EDEMA MACULAR: 2 ISQUEMIA MACULAR: 1 ARC. PERIFOVEAL(CUADS): 4 NEOVASC. RETINAL: 2 ENTRECRUZ.AV/VA: 1 ENTRECRUZ. OTRA RV: 1 RESPETA FOVEA: 2 VENA DRENAJE: 2
TG(mmHg): 14	OJOCL: 1 VITREO CONTRALAT: 1	





NUM.REFERENCIA: 46

EDAD: 60		SEXO: 2	OJO: 2
ANTECD.CV: 2 DIABETES: 2 H <sup>a</sup> .HTA: 1 HTA.EXPL: 2 DISLIPEMIA: 1 TABAQUISMO: 2	SCTRL: 1 SDISMBRUS: 2 SDISMPROGR: 2 SESCOT: 2 SMETAMORF: 1 SMIODESOP: 2	RTEMP: 2 VITREO: 2	
AVLINI: 0,1 AVLFIN: 0,45 AVPINI:6 AVPFIN: 1 REFRACCION: 1	TOCTOP: 328 EVOL (t HASTA FCG): 3287,0 N° SESIONES FCG: 2 SEGUIM (tFCG-FINAL): 1372,0 COMPLICS FCG: 2	INFARTO FS NERV:2 EXUDS.DUROS: 2 ISQUEMIA RETINAL: 3 TIPO OBSTRUCCION: 2 EDEMA MACULAR: 2 ISQUEMIA MACULAR: 1 ARC. PERIFOVEAL(CUADS): 1 NEOVASC. RETINAL: 2 ENTRECRUZ.AV/VA: 1 ENTRECRUZ. OTRA RV: 1 RESPETA FOVEA: 2 VENA DRENAJE: 2	
TG(mmHg): 17	OJOCL: 1 VITREO CONTRALAT: 3		

